

CURRENT CONCEPTS REVIEW

Management of Acromioclavicular Joint Injuries

Xinning Li, MD, Richard Ma, MD, Asheesh Bedi, MD, David M. Dines, MD, David W. Altchek, MD, and Joshua S. Dines, MD

Investigation performed at the Division of Sports Medicine and Shoulder Surgery, Hospital for Special Surgery, New York, NY

- ▶ Acromioclavicular joint injuries are among the most common shoulder girdle injuries in athletes and most commonly result from a direct force to the acromion with the arm in an adducted position.
- ▶ Acromioclavicular joint injuries often present with associated injuries to the glenohumeral joint, including an increased incidence of superior labrum anterior posterior (SLAP) tears that may warrant further evaluation and treatment.
- ▶ Anteroposterior stability of the acromioclavicular joint is conferred by the capsule and acromioclavicular ligaments, of which the posterior and superior ligaments are the strongest. Superior-inferior stability is maintained by the coracoclavicular (conoid and trapezoid) ligaments.
- ▶ Type-I or type-II acromioclavicular joint injuries have been treated with sling immobilization, early shoulder motion, and physical therapy, with favorable outcomes. Return to activity can occur when normal shoulder motion and strength are obtained and the shoulder is asymptomatic as compared with the contralateral normal extremity.
- ▶ The management of type-III injuries remains controversial and is individualized. While a return to the previous level of functional activity with nonsurgical treatment has been documented in a number of case series, surgical reduction and coracoclavicular ligament reconstruction has been associated with a favorable outcome and can be considered in patients who place high functional demands on their shoulders or in athletes who participate in overhead sports.
- ▶ Surgical management is indicated for high-grade (\geq type IV) acromioclavicular joint injuries to achieve anatomic reduction of the acromioclavicular joint, reconstruction of the coracoclavicular ligaments, and repair of the deltotrapizial fascia.
- ▶ Outcomes after surgical reconstruction of the coracoclavicular ligaments have been satisfactory with regard to achieving pain relief and return to functional activities, but further improvements in the biomechanical strength of these constructs are necessary to avoid loss of reduction and creep with cyclic loading.

Peer Review: This article was reviewed by the Editor-in-Chief and one Deputy Editor, and it underwent blinded review by two or more outside experts. The Deputy Editor reviewed each revision of the article, and it underwent a final review by the Editor-in-Chief prior to publication. Final corrections and clarifications occurred during one or more exchanges between the author(s) and copyeditors.

Acromioclavicular joint injuries can result from multiple causes, ranging from a simple fall to high-energy trauma. Athletes, however—particularly those involved in contact sports, skiing,

and cycling—are at an increased risk. Treatment depends on a variety of factors, including the extent of injury, age, and activity level of the patient. Over the last decade, an improved

Disclosure: None of the authors received payments or services, either directly or indirectly (i.e., via his or her institution), from a third party in support of any aspect of this work. One or more of the authors, or his or her institution, has had a financial relationship, in the thirty-six months prior to submission of this work, with an entity in the biomedical arena that could be perceived to influence or have the potential to influence what is written in this work. No author has had any other relationships, or has engaged in any other activities, that could be perceived to influence or have the potential to influence what is written in this work. The complete **Disclosures of Potential Conflicts of Interest** submitted by authors are always provided with the online version of the article.

TABLE I Rockwood Classification of Acromioclavicular Injuries

Type	Acromioclavicular Ligaments	Coracoclavicular Ligaments	Deltopectoral Fascia	Coracoclavicular Interspace Distance*	Radiographic Appearance of Acromioclavicular Joint
I	Sprained	Intact	Intact	Normal	Normal
II	Disrupted	Sprained	Intact	<25%	Widened
III	Disrupted	Disrupted	Disrupted	25% to 100%	Widened
IV	Disrupted	Disrupted	Disrupted	Increased	Clavicle posteriorly displaced (axillary)
V	Disrupted	Disrupted	Disrupted	100% to 300%	N/A†
VI	Disrupted	Disrupted	Disrupted	Decreased	Clavicle displaced inferior to coracoid

*Distance between the superior aspect of the coracoid process and the inferior aspect of the clavicle as measured radiographically.
†N/A = information not available.

understanding of the anatomy and biomechanics of the acromioclavicular joint has led to more anatomical surgical techniques for acromioclavicular joint reconstruction. In this paper, we discuss the clinical and radiographic evaluation, surgical indications, complications, and the outcomes associated with the most commonly used treatment options.

Anatomy and Biomechanics

The acromioclavicular joint is a diarthrodial joint between the medial facet of the acromion and the lateral aspect of the clavicle. Stability in the anterior-posterior plane is provided by the acromioclavicular ligaments, which are thickenings of the joint capsule, with the superior ligament being the strongest¹. Superior-inferior stability is maintained by the trapezoid and conoid coracoclavicular ligaments. The trapezoid ligament, located an average of 25.4 mm in males and 22.9 mm in females from the lateral end of the clavicle, attaches more laterally to the undersurface of the clavicle and provides resistance to acromioclavicular joint compression². The conoid ligament insertion is located medially, an average of 47.2 mm in men and 42.8 mm in females from the lateral edge of the clavicle. It is responsible for about 60% of the restraint to anterior and superior clavicular displacement and rotation¹.

Epidemiology and Classification

The true incidence of acromioclavicular joint injuries seen by clinicians is likely underestimated, as many are not diagnosed or treated³. The spectrum of acromioclavicular joint injury can range from minor sprains and subluxations to complete dislocations. Rockwood⁴ developed a classification system for acromioclavicular joint injuries (Table I). Type I is a sprain of the acromioclavicular joint without a complete tear of the acromioclavicular ligaments or coracoclavicular ligaments. Type II is a tear of the acromioclavicular ligament but not of the coracoclavicular ligaments. A type-III injury involves tears of both the acromioclavicular and coracoclavicular ligaments, with 25% to 100% displacement as compared with that on the contralateral side. Type IV is an acromioclavicular joint injury with the distal part of the clavicle impaled posteriorly into the

trapezoid fascia. In a type-V injury, both the acromioclavicular and coracoclavicular ligaments are completely torn and the displacement is >100% compared with the contralateral side. A type-VI injury is rare; the distal clavicle is displaced inferiorly into the subcoracoid position.

Sprains and incomplete separations are more common than complete injuries. In a review of 520 acromioclavicular joint injuries, more than 300 occurred in the first three decades of life and most were incomplete sprains⁴. Often, acromioclavicular joint injuries are associated with other injuries to the shoulder joint. Tischer et al.⁵ reported that 18.2% (fourteen of seventy-seven) of all patients in their study who were treated for an acute acromioclavicular joint dislocation (Rockwood⁴ types III through V) had concomitant intra-articular shoulder pathology. These included superior labrum anterior posterior (SLAP) lesions in eleven of seventy-seven patients (14%) and rotator cuff injury in three patients (4%). Additionally, four patients sustained fractures of the distal part of the radius, radial head, scapula, and lateral part of the clavicle.

Mechanism of Injury

Typically, acromioclavicular injuries result from direct trauma to the shoulder from a fall or in contact sports when the arm is in an adducted position. The force pushes the acromion inferiorly while the clavicle maintains its anatomic position, resulting in a variable disruption of the acromioclavicular and coracoclavicular ligaments. The downward displacement of the clavicle is primarily resisted through an interlocking of the sternoclavicular and coracoclavicular ligaments, while the anteroposterior displacement is resisted by the acromioclavicular ligaments^{1,6,7}. More severe downward forces may even tear the deltoid and trapezius muscle attachments from the clavicle. A fall on an outstretched hand or flexed elbow may transmit direct forces superiorly to the acromioclavicular joint through the humeral head into the acromion. A traumatic force by a substantial inferior pull through the upper extremity or a lateral directed force as the scapula externally rotates are other uncommon mechanisms for acromioclavicular joint injury.

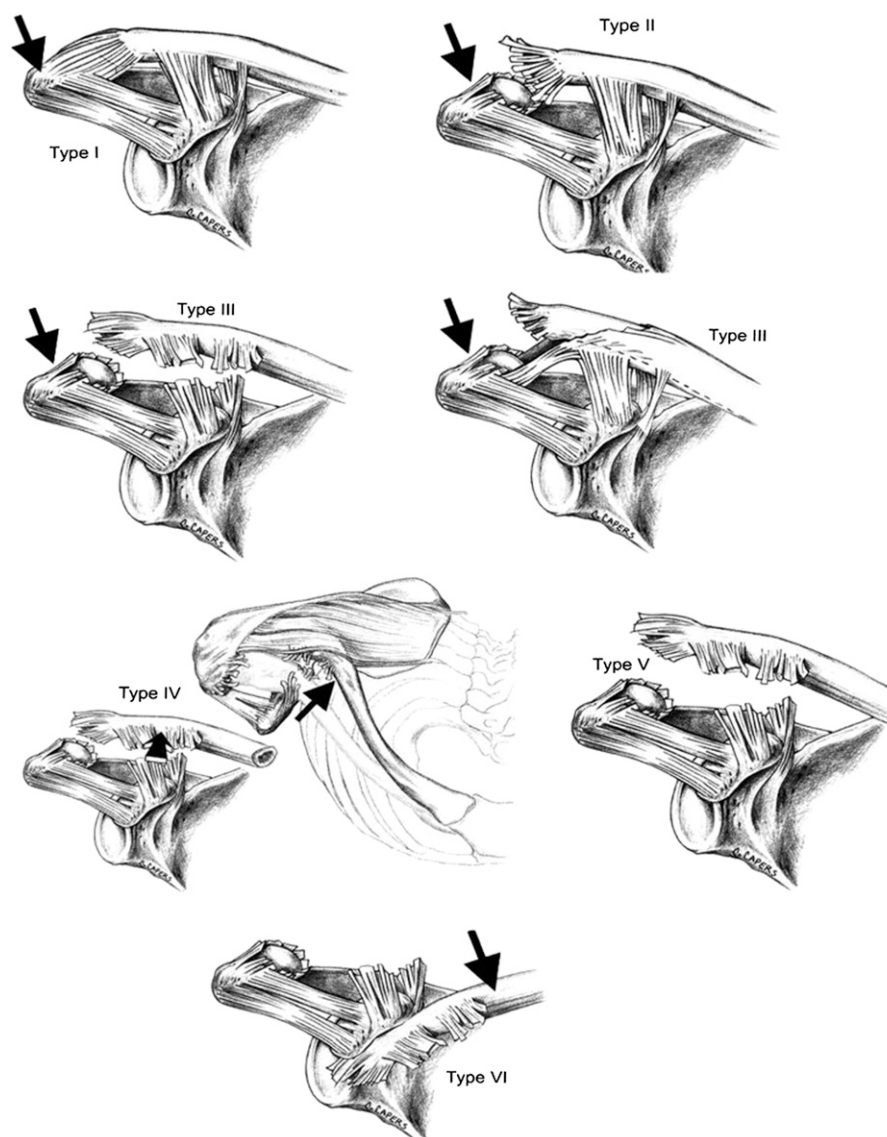


Fig. 1
Illustration of the six different types of acromioclavicular joint injuries in the Rockwood classification system. (Reprinted, with permission, from: Beim GM. Acromioclavicular joint injuries. *J Athl Train.* 2000;35[3]:261-7).

Clinical Presentation

Injury to the acromioclavicular joint should be suspected in any patient who has shoulder trauma with pain in the vicinity of the acromion and clavicle. Most patients with acute acromioclavicular injury will present with the injured upper extremity in an adducted and supported position to alleviate the pain. Localized pain, swelling, and point tenderness around the acromioclavicular joint can be expected acutely. The pain can be accentuated with abduction and cross-body adduction of the arm, which loads the acromioclavicular joint⁸. During the clinical examination, the patient should be in the standing or sitting position, which increases the deformity due to the weight of the arm. Depending on the severity of the injury, tenting of the skin by the distal aspect of the clavicle may occur in the case of type-III or type-V acromioclavicular injuries.

Sternoclavicular joint pain may also be present in type-IV injuries, in which posterior displacement of the distal portion of the clavicle results in concomitant anterior dislocation of the sternoclavicular joint. Patients may also complain of pain in the neck or trapezius muscle, which can occur in type-V and type-VI injuries as a result of soft-tissue injury and stripping of the deltotrapezial fascia. While vascular compromise in an isolated acromioclavicular injury has not been reported, transient paresthesia of the injured limb has been described in a patient with type-VI acromioclavicular injury⁹.

Imaging

The radiographic classification of acromioclavicular joint injuries as described by Tossy et al.¹⁰ and Rockwood⁴ represents a continuum of increased soft-tissue injury. Figure 1 provides an

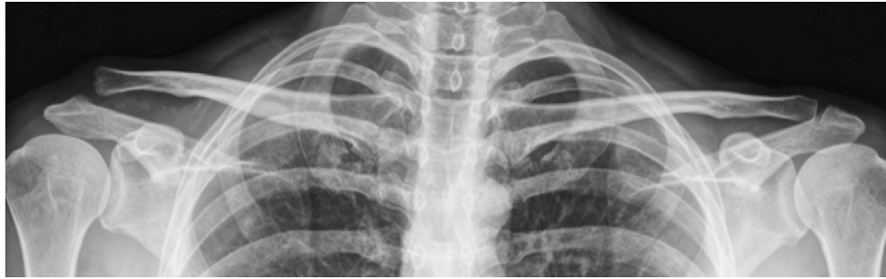

Fig. 2 True anteroposterior standing radiograph of the acromioclavicular joint bilaterally, with the x-ray beam directed with a 10° to 15° cephalic tilt (the Zanca view) and with use of 50% of the exposure that is used in making a standard radiograph of a normal shoulder, comparing the injured right acromioclavicular joint (left side of image) with the normal left acromioclavicular joint (right side of image).

illustration of the Rockwood acromioclavicular joint-injury classification system^{4,10,11}. Radiographs are the initial imaging modality of choice for diagnosis and classification of acromioclavicular injuries. In order to enhance visualization of the acromioclavicular joint, it is necessary to use one-half of the x-ray exposure that is used in a standard radiograph of the shoulder. The Zanca view (in which the x-ray beam is directed with a 10° to 15° cephalic tilt) is the most accurate radiograph to use in visualizing the acromioclavicular joint¹². Due to variations in the anatomy of the acromioclavicular joint, a bilateral Zanca view is recommended to visualize both acromioclavicular joints on a single cassette (Fig. 2). Bearden et al.¹³ reported that the average distance between the superior aspect of the coracoid process and the inferior aspect of the clavicle varies from 1.1 cm to 1.3 cm and that a 40% to 50% difference in coracoclavicular interspace between the normal and affected shoulders indicates complete disruption of the coracoclavicular ligaments, whereas Rockwood and Young documented complete disruption with a side-to-side coracoclavicular interspace difference of just 25%¹⁴. Furthermore, an axillary view is essential in diagnosing type-IV acromioclavicular joint separations, in which posterior displacement of the clavicle occurs. Stress radiographs to differentiate between type-II and type-III injuries have also been described. This is typically done with

the injured and contralateral, normal extremity holding a 10-lb (4.5-kg) weight and comparing the weighted and nonweighted images. Because these radiographs are painful, stress views are not routinely used for imaging of acute acromioclavicular joint injuries^{15,16}.

There is a growing interest in utilizing magnetic resonance imaging (MRI) with acromioclavicular injuries. MRI has the advantage of directly assessing acromioclavicular and coracoclavicular ligamentous disruptions (Fig. 3), whereas radiographs infer ligamentous integrity based on osseous relationships. Nemeč et al.¹⁷ evaluated forty-four patients with acromioclavicular injuries of types I through IV and found that the classification system of Sanders et al.¹¹ for acromioclavicular injuries was only concordant in twenty-three (52.2%) of their patients when radiographs were compared with MR images. In a study utilizing diagnostic arthroscopy to evaluate the incidence of associated injuries in surgically treated type-III to type-V acromioclavicular separations, Tischer et al.⁵ reported an incidence of 18.2% (fourteen of seventy-seven patients) with regard to concomitant intra-articular injuries that required additional surgical intervention. Pauly et al.¹⁸ similarly reported an incidence of 15% (six of forty patients) for concomitant injuries following high-grade acromioclavicular injuries, all of which occurred in type-V separations and required

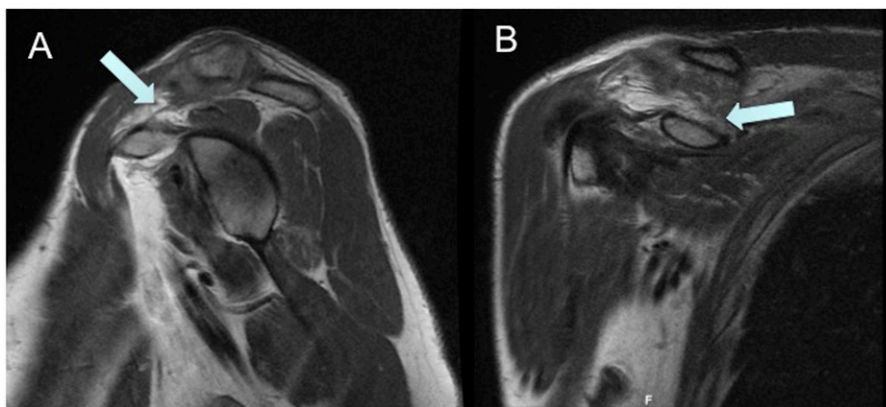


Fig. 3 Magnetic resonance images (MRI) of a patient with type-III acromioclavicular joint injury after direct trauma. Oblique sagittal MRI (A) demonstrates rupture of the coracoclavicular ligament (arrow), which is confirmed on the coronal MRI (B.)

arthroscopic surgical intervention. Both author groups concluded that preoperative MRI, particularly in patients with type-V acromioclavicular injuries, may be helpful in identifying potential associated injuries that may require surgical intervention.

Management of Acromioclavicular Joint Injuries

Types I and II

Nonsurgical management has been recommended for type-I and type-II acromioclavicular joint injuries^{10,19,20}, with most authors recommending simple sling immobilization. Other therapeutic modalities include simple analgesia, anti-inflammatory medications, ice therapy, activity modification, and complete rest. Typically, one week of immobilization is needed for type-I acromioclavicular injuries, while type-II injuries may require a longer period of time. The sling should be discontinued once the patient is asymptomatic, and physical therapy should then be started with both passive and active shoulder motion. Contact sports and heavy lifting should be avoided until the patient is free of pain and has symmetric shoulder range of motion and strength relative to the uninjured extremity. Pain in the acromioclavicular joint may persist for as long as six months after the injury, with up to 33% of patients experiencing continued pain and acromioclavicular instability at longer-term (i.e., a mean of 6.3 years [range, four to eight years]) follow-up²¹.

Park et al.²² reported that type-I injuries immobilized for an average of 19.5 days resulted in six weeks of disability time and a shoulder rating score of 94 points. Within that series, type-II injuries required longer immobilization (twenty-seven days), resulting in a similar period of disability and a shoulder rating score of 90 points. The shoulder rating score used in this study was a nonvalidated scoring system based on 100 points, and it was designed to evaluate the wound, deformity, range of motion, pain, and any postoperative complications. With short-term follow-up, Shaw et al.²³ reported that up to 40% (fourteen of thirty-five) of patients had pain at six months following injury and that this percentage decreased to 14% (five of thirty-five) at the one-year time point. With midterm follow-up, several authors reported good-to-excellent functional outcomes, with an 80% to 90% patient satisfaction rating^{24,25}. However, in the United States Naval Academy population, Bergfeld et al.²⁶ found that up to 9% (nine of ninety-seven patients with type-I injuries) and 23% (seven of thirty-one patients with type-II injuries) of patients reported severe pain with limitation of activities at follow-up times that ranged from six months to 3.5 years. In contrast, Reichkender et al.²⁷ reported excellent results and an average Constant score of 97 in nineteen patients with type-II injury who had been treated with nonsurgical management. In a study with long-term follow-up, Mouhsine et al.²¹ reported a Constant score²⁸ of 82 in thirty-three patients at a mean follow-up of 6.2 years, with 48% (sixteen of thirty-three) having persistent acromioclavicular joint symptoms and with 27% (nine of thirty-three) requiring surgical intervention at a mean of more than two years after the initial injury. Mikek²⁹ also reported impairment of shoulder function in 52% (twelve of twenty-three) of patients with type-

I or type-II injuries who had been treated nonsurgically and had follow-up greater than ten years. The mean Constant score of 70.5, UCLA (University of California, Los Angeles) score³⁰ of 24.1, and simple shoulder score³¹ of 9.7 were all significantly lower than the scores of the contralateral, normal shoulder.

Type III

The management of type-III acromioclavicular joint injuries remains controversial. Most studies are case series with Level-IV evidence, and there are very few reports with Level-II (Table II) or Level-III (Table III) evidence available to guide treatment decisions³². While most authors have obtained good-to-excellent results with nonsurgical management in patients with type-III injuries^{24,33-38}, others have reported persistent pain and residual symptoms associated with the acromioclavicular joint on final follow-up^{20,35,39}. Thus, to maximize function, some authors have advocated surgery for acute type-III acromioclavicular joint injuries in young and active patients⁴⁰⁻⁴³. As a result, there is no consensus among orthopaedic surgeons with regard to the management of type-III acromioclavicular joint injuries. Therefore, individual assessment of each patient is essential, as the optimal treatment (surgical or nonsurgical) for an athlete who plays overhead sports and places high functional demands on the acromioclavicular joint may be different for older, less active patients.

Nonsurgical Management

Several authors have reported satisfactory outcomes in patients with type-III acromioclavicular separations that were managed nonsurgically. Glick et al.²⁵ reported satisfactory outcomes with no substantial functional disability in thirty-five patients who had a mean follow-up of three years after nonsurgical treatment. Dias et al.⁴⁴ reviewed forty-four patients approximately five years after nonsurgical management and reported good-to-excellent results in all patients except one, who had persistent subluxation of the acromioclavicular joint. In addition, 55% of the patients had mild symptoms over the acromioclavicular joint, 82% had obvious deformity, and 11% had a decrease in shoulder abduction of 20°; however, these findings did not limit the overall function of the patients. The long-term results in this same cohort of patients were reported by Rawes and Dias⁴⁵ at an average of 12.5 years after injury. Of the thirty patients reviewed (fourteen patients were lost to follow-up), the acromioclavicular joint remained subluxated or dislocated in all patients; however, 97% still had good-to-excellent results according to the classification system of Imatani et al.⁴⁶. Bjerneld et al.²⁴ also reported good-to-excellent results in 91% of patients (thirty of thirty-three) whose type-III separations were treated nonsurgically. The authors also noted that a reduction of the acromioclavicular joint was not necessary, as there is a potential for healing and the ability to adapt after injury. Schlegel et al.³⁵ prospectively evaluated twenty-five patients whose type-III injuries had been managed nonsurgically. In comparing the injured shoulder to the contralateral, normal shoulder, there was no significant difference in range of motion and rotational strength. However, a 17% decrease in bench-press strength was found on the side of

TABLE II Studies with Level-II Evidence or Less in Which Nonsurgical and Surgical Management of Type-III Acromioclavicular Joint Injuries Was Compared*

Study	Total Number of Patients	Follow-up Period (Number of Patients Who Completed Follow-up)	Outcome	Complications
Imatani et al. ⁴⁶ (1975)	30	>12 months (12 NS and 11 S)	Shoulder Scoring Scale (nonvalidated 100-point scale) ● NS = 58% (good to excellent) ● S = 45% (good to excellent) Note: Return to work or activities was not assessed.	In the surgical group: ● Screw pullout and loss of reduction (2) Note: Surgical group had more calcification in coracoclavicular interval, but this finding did not correlate with outcome.
Larsen et al. ⁴⁹ (1986)	84	13 months (40 NS and 39 S)	Shoulder Scoring Scale (nonvalidated 12-point scale) ● NS = 98% (good to excellent) ● S = 98% (good to excellent) Note: Surgically treated patients took longer time off from work (p = 0.067).	In the surgical group: ● Reoperation due to residual pain (excision of distal portion of clavicle) (2) ● Migration of Kirschner wire (1) ● Broken Kirschner wire (1) ● Superficial infections (6) In the nonsurgical group: ● Three patients also had operation (persistent pain)
Bannister et al. ²⁰ (1989)	60	1 and 4 years (33 NS and 27 S; [2 lost to follow-up at 1 year and 6 lost to follow-up at 4 years])	Shoulder Scoring Scale (nonvalidated 100-point scale) At 1 year: ● NS = 88% (good to excellent) ● S = 77% (good to excellent) At 4 years: ● NS = 100% (good to excellent) ● S = 74% (good to excellent) Note: Surgically treated patients returned to work later than patients managed nonsurgically (p < 0.05)	In the surgical group: Reoperation (total of 5 patients) ● Screw cut out (2) ● Screw broken (1) ● Painful subluxation (2) Note: Loss of reduction in 35% of patients when coracoclavicular screw was removed. In the nonsurgical group: Reoperation (total of four patients) ● Shoulder weakness (1) ● Appearance (1) ● Painful subluxation (2)

*NS = nonsurgically treated patients, and S = surgically treated patients.

the injured shoulder, and 16% of the patients believed that their outcome was suboptimal, with one patient electing surgical intervention. Furthermore, Gumina et al.⁴⁷ reported that 70.6% (twenty-four of thirty-four) and 58.3% (fourteen of the twenty-four) of patients treated nonsurgically after type-III acromioclavicular joint injury developed scapular dyskinesia and SICK scapula syndrome (scapular malposition, inferior medial border prominence, coracoid pain and malposition, and dyskinesia of scapular movement), respectively⁴⁸.

Nonsurgical Versus Surgical Management

Surgical management of type-III acromioclavicular joint separation remains controversial. While most patients have good-to-excellent functional outcomes after nonsurgical management and can return to their previous level of activity^{24,36}, some authors recommend early surgical intervention in patients with higher functional demands^{20,44}. There are three randomized prospective trials^{20,46,49} (Table II) and seven nonrandomized studies^{33,34,41,50-53} (Table III) that have directly

TABLE III Studies with Level-III Evidence or Less in Which Nonsurgical and Surgical Management of Type-III Acromioclavicular Joint Injuries Were Compared*

Study	Total Number of Patients	Follow-up Period (Number of Patients Who Completed Follow-up)	Outcome	Complications
Taft et al. ³³ (1987)	127	9.5 yrs (75 NS, including 12 who remained untreated) 10.8 yrs (52 S)	12-point system based on subjective, objective, and radiographic ratings. <ul style="list-style-type: none"> ● NS = 8.4 ● S = 9.4 ● NT = 8.2 ● Poor results (<6 of 12 points) seen in NS (10%), S (6%), and NT (8%) 	In the surgical group: 52 (100% of surgical patients) <ul style="list-style-type: none"> ● Migration of pin (12) ● Hardware breakage (6) ● Bone erosions (10) ● Hematoma (5) ● Infection (4) ● Arthritis (13) ● Miscellaneous (2) In the nonsurgical group: 33 (52% of the 63 treated patients) <ul style="list-style-type: none"> ● Skin necrosis (4) ● Arthritis (27) ● Miscellaneous (2)
Press et al. ⁵² (1997)	26	32.9 months (10 NS and 16 S)	In the nonsurgical group: <ul style="list-style-type: none"> ● Return to work and sports was quicker and patients spent less time in immobilization ($p < 0.05$). In the surgical group: <ul style="list-style-type: none"> ● Quicker pain-free status and better subjective impression of range of motion, functional limitations, cosmesis, and long-term satisfaction ($p < 0.05$). Note: No difference between the 2 groups with regard to objective shoulder range of motion, muscle strength, and neurovascular findings.	N/A
Gstettner et al. ⁴¹ (2008)	41	34 months (17 NS and 24 S)	In the nonsurgical group: <ul style="list-style-type: none"> ● Oxford shoulder score = 18.7 ● Simple shoulder score = 9.9 ● Constant score = 80.7 ● Good to excellent results seen in 58.8% of patients In the surgical group: <ul style="list-style-type: none"> ● Oxford shoulder score = 16.0 ● Simple shoulder score = 11.3 ● Constant score = 90.4 ● Good to excellent results seen in 87.5% of patients Note: Constant scores were significantly better in the surgical group. Other scores showed no significant difference.	In the nonsurgical group: <ul style="list-style-type: none"> ● All patients had osteophytes on the caudal side of the lateral end of the clavicle, but these were not symptomatic. In the surgical group: <ul style="list-style-type: none"> ● Radiographic arthrosis in 54% (13 of 24) ● Complications in 12.5% (3 of 24) (2 required revision surgery) Note: Authors recommended surgery (hook plate) in younger and active patients for type-III AC joint injury due to better functional results compared with nonsurgical management.

TABLE III (continued)

Study	Total Number of Patients	Follow-up Period (Number of Patients Who Completed Follow-up)	Outcome	Complications
Galpin et al. ⁵¹ (1985)	37	33.7 months (21 NS) 35.0 months (16 S)	In the nonsurgical group: <ul style="list-style-type: none"> ● Pain-free at 2.8 months ● Time missed from sports = 1.7 months ● Return to work at 2.6 weeks ● Subjective pain-free status in 71% (15 of 21) ● Normal strength in 71% (15 of 21) In the surgical group: <ul style="list-style-type: none"> ● Pain-free status (4.5 months) ● Time missed from sports (2.2 months) ● Return to work (6.8 weeks) ● Subjective pain-free status in 75% (12 of 16) ● Normal strength in 75% (12 of 16) 	In the nonsurgical group: <ul style="list-style-type: none"> ● N/A In the surgical group: <ul style="list-style-type: none"> ● Reoperation in 13% (2 of 16) ● screw pull out (1) ● hardware irritation (1)
Calvo et al. ³⁴ (2006)	43	40.5 months (11 NS) 122.8 months (32 S)	In the nonsurgical group: <ul style="list-style-type: none"> ● Imatani shoulder score = 94.1, good to excellent in 82% (9 of 11) In the surgical group: <ul style="list-style-type: none"> ● Imatani shoulder score = 93.7, good to excellent in 97% (31 of 32) 	In the nonsurgical group: <ul style="list-style-type: none"> ● Posttraumatic coracoclavicular ligament ossification in 2 of 11. ● Osteoarthritis of the AC joint in 27% (3 of 11). In the surgical group: <ul style="list-style-type: none"> ● Posttraumatic CC ligament ossification in 19 of 32. ● Unattractive scar (7) ● Superficial infection (1) ● Pin migration (7) ● Osteoarthritis of the AC joint in 81% (26 of 32).
Fraschini et al. ⁵³ (2010)	90	1 month (30 NS) 6 months (30 S [Dacron graft]) 15 months (30 S [LARS])	In the nonsurgical group: <ul style="list-style-type: none"> ● Good to excellent (0%) ● UCLA (16.2) ● SPADI (65) In the surgical group (Dacron): <ul style="list-style-type: none"> ● Good to excellent (53%) ● UCLA (27.9) ● SPADI (18) In the surgical group (LARS): <ul style="list-style-type: none"> ● Good to excellent (93.3%) ● UCLA (28.4) ● SPADI (16) 	In the nonsurgical group: <ul style="list-style-type: none"> ● N/A In the surgical group (Dacron): <ul style="list-style-type: none"> ● Rupture of Dacron (7) ● Foreign body reaction (4) ● Clavicular fracture (1) ● Coracoid fracture (1) ● Total = 43% In the surgical group (LARS): <ul style="list-style-type: none"> ● Rupture of ligament (1) ● Total = 3.3%

TABLE III (continued)

Study	Total Number of Patients	Follow-up Period (Number of Patients Who Completed Follow-up)	Outcome	Complications
Fremerey et al. ⁵⁰ (2005)	97	6.5 years (46 NS; 38 achieved full follow-up) 6.1 years (51 S; 42 achieved full follow-up)	In the nonsurgical group at time of final follow-up (n = 38): <ul style="list-style-type: none"> ● Pain-free status in 89% (34 of 38) ● UCLA score good to excellent in 95% (36 of 38) ● Constant-Murley shoulder outcome score good to excellent in 97% (37 of 38) ● No loss of strength in 92% (35 of 38) In the surgical group at time of final follow-up (n = 42): <ul style="list-style-type: none"> ● Pain-free status in 86% (36 of 42) ● UCLA score good to excellent in 98% (41 of 42) ● Constant-Murley Shoulder Outcome score excellent in 98% (41 of 42) ● No loss of strength in 90% (38 of 42) 	In the nonsurgical group: <ul style="list-style-type: none"> ● Posttraumatic arthritis in the AC joint in 12% (4 of 33 evaluated patients) ● Reoperation for pain at the AC joint (AC resection) (1) ● Moderate pain with work (in 1 of 5 in the hard-working laborer group) ● Calcification in the CC ligament in 37% (14 of 38) In the surgical group: <ul style="list-style-type: none"> ● Posttraumatic arthritis in the AC joint in 15% (5 of 34 evaluated patients) ● Reoperation for pain at the AC joint (1) ● Severe pain at rest (in 1 of 7 in the hard-working laborer group) ● Calcification in the CC ligament in 55% (23 of 42)
*NS = nonsurgically treated patients, S = surgically treated patients, NT = untreated patients, N/A = information not available, AC = acromioclavicular, LARS = ligament augmentation and reconstruction system, UCLA = University of California, Los Angeles shoulder scale score, SPADI = Shoulder Pain and Disability Index score, and CC = coracoclavicular.				

compared the outcomes of nonsurgical versus surgical intervention in the management of type-III acromioclavicular separations. Two additional prospective randomized clinical trials are ongoing, with no results published⁵⁴. A total of 174 patients were evaluated in the three prospective studies in which patients were randomized to either nonsurgical or surgical treatment. Nonsurgical management involved either placing the arm in a broad sling²⁰, Velpeau bandage⁴⁶, or arm sling plus a swathe⁴⁹. Surgical intervention involved reduction of the displaced acromioclavicular joint, fixation of the clavicle to the coracoid with an Arbeitsgemeinschaft für Osteosynthesefragen (AO) cancellous or malleolar screw (with or without a washer), and then pinning the acromioclavicular joint with two Kirschner wires (Tables II and III)^{20,36,46,49,55}. Smith et al.⁵⁶ performed a meta-analysis of six nonrandomized studies (380 patients) comparing surgical and nonsurgical treatment of acute type-III acromioclavicular joint injuries and found no difference in strength, pain, throwing ability, and incidence of acromioclavicular joint osteoarthritis between the two groups ($p > 0.05$). However, the surgical group had significantly better cosmetic appearance ($p < 0.0001$) and significantly greater duration of sick leave ($p < 0.001$), with one study reporting significantly better Constant scores at the time of final follow-up ($p = 0.003$). Furthermore, there

was no difference in the maintenance of anatomical reduction between the two groups; thus, complete anatomical reduction was not a requirement for optimal functional outcome.

In summary, there is currently a lack of studies with a high level of evidence that evaluate nonsurgical compared with surgical management of type-III acromioclavicular joint injuries. The three prospective randomized studies are over twenty years old and involve surgical fixation methods that are not currently utilized. More recent studies are limited by retrospective study design, patient heterogeneity, and lack of standardized outcome measurements^{22,33,34,41,50,52,56}. On the basis of the available literature, the current consensus is that no functional difference is demonstrated between the two groups; however, a higher overall complication rate and longer time before return to previous level of activity or work is seen in the surgical group. Hence, the recommendation for treatment of uncomplicated type-III acromioclavicular joint injury is to start with an initial trial of nonsurgical treatment for three to four months. Surgical management should be considered in patients who have significant acromioclavicular deformity, tenting of the skin, or persistent pain despite nonsurgical management, or in patients who place a higher functional demand (work or sports) on the injured shoulder.

Types IV, V, and VI**Surgical Management—Techniques and Outcomes**

Surgical intervention is indicated for patients with type-III acromioclavicular injuries for which nonsurgical treatment has been unsuccessful as well as for medically stable patients with type-IV, type-V, or type-VI acromioclavicular joint injuries. Type-IV and type-VI injuries are extremely rare, and most reported outcome data are presented either as part of a small case series or as a case report⁵⁷⁻⁵⁹. Numerous surgical techniques have been described in the treatment of type-III or type-V acromioclavicular joint injuries, but not one technique has been shown to be clinically superior to another^{36,42,43,60-71}. Historically, surgical management includes open reduction, direct repair of the acromioclavicular capsule, and rigid internal fixation of the acromioclavicular joint^{72,73}. Complications and residual pain can be attributed to the implants and progression of arthritis in the acromioclavicular joint. Weaver and Dunn initially described their classic technique, which included resecting the distal portion of the clavicle and transferring the coracoacromial ligament from the acromion to the clavicle without internal fixation⁷⁴. Since their initial study, a myriad of surgical techniques for the management of acromioclavicular joint injuries have been reported. Despite all of the surgical modifications to the original operation, five key elements remain essential to a successful outcome with surgical management of acromioclavicular joint injuries: (1) anatomic and accurate reduction of the acromioclavicular joint to correct superior displacement and anterior-to-posterior translation; (2) direct repair (in patients with acute injury) or reconstruction (in patients with chronic injury) of the coracoclavicular ligament, depending on the clinical setting; (3) supplementation or protection of the coracoclavicular ligament repair or reconstruction with synthetic material (suture or tape) or a rigid implant to maintain acromioclavicular joint stability during the acute phases of healing; (4) repair of the deltoid and trapezial fascia; and (5) distal clavicular resection in patients with chronic acromioclavicular injuries for which there is radiographic or clinical evidence of acromioclavicular osteoarthritis.

With recent advancements in instrumentation and arthroscopic techniques, there has been a recent increased use of arthroscopically assisted or all-arthroscopic reconstruction of the coracoclavicular ligament with graft or synthetic material⁷¹. The purported advantage is to evaluate and treat concomitant intra-articular shoulder pathology, minimize soft-tissue dissection, reduce skin or wound complications, and facilitate rehabilitation and earlier return to work or sports activities^{61,63,64}. However, the disadvantage may be with regard to the technical difficulty and the increased surgical costs that are associated with arthroscopic reconstructive techniques. Given the heterogeneity among study populations and surgical techniques, it is difficult, on the basis of the current available evidence, to state a superiority of a particular repair and reconstruction technique.

Depending on the type of operation performed, overall complications after surgery may include superficial infection, implant irritation and/or migration, loss of acromioclavicular reduction, and persistent pain and instability. Aseptic foreign-

body reactions and erosion of the clavicle have also been associated with synthetic polyester fiber (Dacron; DuPont, Kinross, North Carolina) graft or cerclage material, respectively^{75,76}. Distal clavicular osteolysis or osteoarthritis has also been associated with acromioclavicular joint fixation⁷⁷. Neurologic injuries range from local skin dysesthesias to arm weakness due to nerve root traction or injury to the suprascapular nerve secondary to aggressive acromioclavicular resection⁷⁸.

Summary

Acromioclavicular joint injuries are common shoulder injuries that often result from direct trauma sustained during participation in contact sports. Anterior-to-posterior stability is provided by the acromioclavicular ligaments, while superior stability is provided by the coracoclavicular ligaments. Clinicians should be cognizant of concomitant shoulder injuries (SLAP or rotator cuff tears) that may be associated with more severe acromioclavicular injuries. A bilateral acromioclavicular joint radiograph (the Zanca view) is the initial imaging modality of choice for management of acromioclavicular injuries. When appropriate, MRI may be useful to further assess the degree of injury to acromioclavicular joint stabilizers while evaluating for concomitant intra-articular glenohumeral injuries. Nonsurgical management should be employed for type-I and type-II injuries; however, patients may have persistent symptoms at the acromioclavicular joint that require surgical intervention. Management of type-III acromioclavicular joint injury remains controversial. The majority of patients do well with nonsurgical management; however, individual assessment of each patient is essential because the optimal treatment may differ depending on an individual's functional goals. Surgical repair or reconstruction is recommended in patients with type-III injuries for which nonsurgical management has failed and for type-IV, type-V, and type-VI acromioclavicular joint injuries. Outcomes after surgical reconstruction of the coracoclavicular ligaments have been largely satisfactory, despite some loss of reduction over time. ■

Xinning Li, MD
Richard Ma, MD
David M. Dines, MD
David W. Altchek, MD
Joshua S. Dines, MD
Hospital for Special Surgery,
535 East 70th Street,
New York, NY 10021.
E-mail address for X. Li: Xinning.li@gmail.com.
E-mail address for R. Ma: richardmamd@gmail.com.
E-mail address for D.M. Dines: Ddinesmd98@aol.com.
E-mail address for D.W. Altchek: altchekd@hss.edu.
E-mail address for J.S. Dines: jdinesmd@gmail.com

Asheesh Bedi, MD
University of Michigan,
24 Frank Lloyd Wright Drive,
Ann Arbor, MI 48105.
E-mail address: abedi@med.umich.edu

References

1. Fukuda K, Craig EV, An KN, Cofield RH, Chao EY. Biomechanical study of the ligamentous system of the acromioclavicular joint. *J Bone Joint Surg Am.* 1986 Mar;68(3):434-40.
2. Rios CG, Arciero RA, Mazzocca AD. Anatomy of the clavicle and coracoid process for reconstruction of the coracoclavicular ligaments. *Am J Sports Med.* 2007 May;35(5):811-7. Epub 2007 Feb 09.
3. Copeland S. *Shoulder surgery.* London: WB Saunders; 1997.
4. Rockwood CA Jr. Injuries to the acromioclavicular joint. In: Rockwood CA Jr, Green DP. *Fractures in adults, vol 1, 2nd ed.* Philadelphia: JB Lippincott; 1984. p 860-910.
5. Tischer T, Salzmann GM, El-Azab H, Vogt S, Imhoff AB. Incidence of associated injuries with acute acromioclavicular joint dislocations types III through V. *Am J Sports Med.* 2009 Jan;37(1):136-9. Epub 2008 Aug 25.
6. Debski RE, Parsons IM 4th, Woo SL, Fu FH. Effect of capsular injury on acromioclavicular joint mechanics. *J Bone Joint Surg Am.* 2001 Sep;83(9):1344-51.
7. Lee KW, Debski RE, Chen CH, Woo SL, Fu FH. Functional evaluation of the ligaments at the acromioclavicular joint during anteroposterior and superoinferior translation. *Am J Sports Med.* 1997 Nov-Dec;25(6):858-62.
8. Chronopoulos E, Kim TK, Park HB, Ashenbrenner D, McFarland EG. Diagnostic value of physical tests for isolated chronic acromioclavicular lesions. *Am J Sports Med.* 2004 Apr-May;32(3):655-61.
9. Gerber C, Rockwood CA Jr. Subcoracoid dislocation of the lateral end of the clavicle. A report of three cases. *J Bone Joint Surg Am.* 1987 Jul;69(6):924-7.
10. Tossy JD, Mead NC, Sigmund HM. Acromioclavicular separations: useful and practical classification for treatment. *Clin Orthop Relat Res.* 1963;28:111-9.
11. Sanders JO, Lyons FA, Rockwood CA Jr. Management of dislocations of both ends of the clavicle. *J Bone Joint Surg Am.* 1990 Mar;72(3):399-402.
12. Zanca P. Shoulder pain: involvement of the acromioclavicular joint. (Analysis of 1,000 cases). *Am J Roentgenol Radium Ther Nucl Med.* 1971 Jul;112(3):493-506.
13. Bearden JM, Hughston JC, Whatley GS. Acromioclavicular dislocation: method of treatment. *J Sports Med.* 1973;1(4):5-17.
14. Rockwood CA Jr, Young DC. Disorders of the acromioclavicular joint. In: Rockwood CA Jr, Matsen FA III, eds. *The shoulder.* Philadelphia: WB Saunders; 1990. p 413-76.
15. Bossart PJ, Joyce SM, Manaster BJ, Packer SM. Lack of efficacy of 'weighted' radiographs in diagnosing acute acromioclavicular separation. *Ann Emerg Med.* 1988 Jan;17(1):20-4.
16. Melenevsky Y, Yablou CM, Ramappa A, Hochman MG. Clavicle and acromioclavicular joint injuries: a review of imaging, treatment, and complications. *Skeletal Radiol.* 2011 Jul;40(7):831-42. Epub 2010 Jun 06.
17. Nemeč U, Oberleitner G, Nemeč SF, Gruber M, Weber M, Czerny C, Krestan CR. MRI versus radiography of acromioclavicular joint dislocation. *AJR Am J Roentgenol.* 2011 Oct;197(4):968-73.
18. Pauly S, Gerhardt C, Haas NP, Scheibel M. Prevalence of concomitant intra-articular lesions in patients treated operatively for high-grade acromioclavicular joint separations. *Knee Surg Sports Traumatol Arthrosc.* 2009 May;17(5):513-7. Epub 2008 Nov 20.
19. Allman FL Jr. Fractures and ligamentous injuries of the clavicle and its articulation. *J Bone Joint Surg Am.* 1967 Jun;49(4):774-84.
20. Bannister GC, Wallace WA, Stableforth PG, Hutson MA. The management of acute acromioclavicular dislocation. A randomised prospective controlled trial. *J Bone Joint Surg Br.* 1989 Nov;71(5):848-50.
21. Mouhsine E, Garofalo R, Crevoisier X, Farron A. Grade I and II acromioclavicular dislocations: results of conservative treatment. *J Shoulder Elbow Surg.* 2003 Nov-Dec;12(6):599-602.
22. Park JP, Arnold JA, Coker TP, Harris WD, Becker DA. Treatment of acromioclavicular separations. A retrospective study. *Am J Sports Med.* 1980 Jul-Aug;8(4):251-6.
23. Shaw MB, McInerney JJ, Dias JJ, Evans PA. Acromioclavicular joint sprains: the post-injury recovery interval. *Injury.* 2003 Jun;34(6):438-42.
24. Bjerneld H, Hovelius L, Thorling J. Acromio-clavicular separations treated conservatively. A 5-year follow-up study. *Acta Orthop Scand.* 1983 Oct;54(5):743-5.
25. Glick JM, Milburn LJ, Haggerty JF, Nishimoto D. Dislocated acromioclavicular joint: follow-up study of 35 unreduced acromioclavicular dislocations. *Am J Sports Med.* 1977 Nov-Dec;5(6):264-70.
26. Bergfeld JA, Andrich JT, Clancy WG. Evaluation of the acromioclavicular joint following first- and second-degree sprains. *Am J Sports Med.* 1978 Jul-Aug;6(4):153-9.
27. Reichkender M, Rangger C, Dessl A, Ulmer H. [Comparison and outcome of grade II and III acromioclavicular joint injuries]. *Unfallchirurg.* 1996 Oct;99(10):778-83. German.
28. Constant CR, Murley AH. A clinical method of functional assessment of the shoulder. *Clin Orthop Relat Res.* 1987 Jan;(214):160-4.
29. Mikek M. Long-term shoulder function after type I and II acromioclavicular joint disruption. *Am J Sports Med.* 2008 Nov;36(11):2147-50. Epub 2008 Jun 26.
30. Amstutz HC, Sew Hoy AL, Clarke IC. UCLA anatomic total shoulder arthroplasty. *Clin Orthop Relat Res.* 1981 Mar-Apr;(155):7-20.
31. L'Insalata JC, Warren RF, Cohen SB, Altchek DW, Peterson MG. A self-administered questionnaire for assessment of symptoms and function of the shoulder. *J Bone Joint Surg Am.* 1997 May;79(5):738-48.
32. Wright JG, Swiontkowski MF, Heckman JD. Introducing levels of evidence to the journal. *J Bone Joint Surg Am.* 2003 Jan;85(1):1-3.
33. Taft TN, Wilson FC, Oglesby JW. Dislocation of the acromioclavicular joint. An end-result study. *J Bone Joint Surg Am.* 1987 Sep;69(7):1045-51.
34. Calvo E, López-Franco M, Arribas IM. Clinical and radiologic outcomes of surgical and conservative treatment of type III acromioclavicular joint injury. *J Shoulder Elbow Surg.* 2006 May-Jun;15(3):300-5.
35. Schlegel TF, Burks RT, Marcus RL, Dunn HK. A prospective evaluation of untreated acute grade III acromioclavicular separations. *Am J Sports Med.* 2001 Nov-Dec;29(6):699-703.
36. Spencer EE Jr. Treatment of grade III acromioclavicular joint injuries: a systematic review. *Clin Orthop Relat Res.* 2007 Feb;455(Feb):38-44.
37. Hootman JM. Acromioclavicular dislocation: conservative or surgical therapy. *J Athl Train.* 2004 Mar;39(1):10-1.
38. Rolf O, Hann von Weyhern A, Ewers A, Boehm TD, Gohlke F. Acromioclavicular dislocation Rockwood III-V: results of early versus delayed surgical treatment. *Arch Orthop Trauma Surg.* 2008 Oct;128(10):1153-7. Epub 2007 Nov 22.
39. Wojtys EM, Nelson G. Conservative treatment of Grade III acromioclavicular dislocations. *Clin Orthop Relat Res.* 1991 Jul;(268):112-9.
40. Ryhänen J, Niemelä E, Kaarela O, Raatikainen T. Stabilization of acute, complete acromioclavicular joint dislocations with a new C hook implant. *J Shoulder Elbow Surg.* 2003 Sep-Oct;12(5):442-5.
41. Gstettner C, Tauber M, Hitzl W, Resch H. Rockwood type III acromioclavicular dislocation: surgical versus conservative treatment. *J Shoulder Elbow Surg.* 2008 Mar-Apr;17(2):220-5. Epub 2008 Feb 04.
42. Leidel BA, Braunstein V, Kirchoff C, Pilotto S, Mutschler W, Biberthaler P. Consistency of long-term outcome of acute Rockwood grade III acromioclavicular joint separations after K-wire transfixation. *J Trauma.* 2009 Jun;66(6):1666-71.
43. Lizaur A, Sanz-Reig J, Gonzalez-Parreño S. Long-term results of the surgical treatment of type III acromioclavicular dislocations: an update of a previous report. *J Bone Joint Surg Br.* 2011 Aug;93(8):1088-92.
44. Dias JJ, Steingold RF, Richardson RA, Tesfayohannes B, Gregg PJ. The conservative treatment of acromioclavicular dislocation. Review after five years. *J Bone Joint Surg Br.* 1987 Nov;69(5):719-22.
45. Rawes ML, Dias JJ. Long-term results of conservative treatment for acromioclavicular dislocation. *J Bone Joint Surg Br.* 1996 May;78(3):410-2.
46. Imatani RJ, Hanlon JJ, Cady GW. Acute, complete acromioclavicular separation. *J Bone Joint Surg Am.* 1975 Apr;57(3):328-32.
47. Gumina S, Carbone S, Postacchini F. Scapular dyskinesia and SICK scapula syndrome in patients with chronic type III acromioclavicular dislocation. *Arthroscopy.* 2009 Jan;25(1):40-5. Epub 2008 Oct 10.
48. Burkhart SS, Morgan CD, Kibler WB. The disabled throwing shoulder: spectrum of pathology Part III: The SICK scapula, scapular dyskinesia, the kinetic chain, and rehabilitation. *Arthroscopy.* 2003 Jul-Aug;19(6):641-61.
49. Larsen E, Bjerg-Nielsen A, Christensen P. Conservative or surgical treatment of acromioclavicular dislocation. A prospective, controlled, randomized study. *J Bone Joint Surg Am.* 1986 Apr;68(4):552-5.
50. Fremerey R, Freitag N, Bosch U, Lobenhoffer P. Complete dislocation of the acromioclavicular joint: operative versus conservative treatment. *J Orthop Traumatol.* 2005 Dec; 6(4):174-8.
51. Galpin RD, Hawkins RJ, Grainger RW. A comparative analysis of operative versus nonoperative treatment of grade III acromioclavicular separations. *Clin Orthop Relat Res.* 1985 Mar;(193):150-5.
52. Press J, Zuckerman JD, Gallagher M, Cuomo F. Treatment of grade III acromioclavicular separations. Operative versus nonoperative management. *Bull Hosp Jt Dis.* 1997;56(2):77-83.
53. Fracchini G, Ciampi P, Scotti C, Ballis R, Peretti GM. Surgical treatment of chronic acromioclavicular dislocation: comparison between two surgical procedures for anatomic reconstruction. *Injury.* 2010;41(11):1103-6.
54. Tamaoki MJ, Belloti JC, Lenza M, Matsumoto MH, Gomes Dos Santos JB, Faloppa F. Surgical versus conservative interventions for treating acromioclavicular dislocation of the shoulder in adults. *Cochrane Database Syst Rev.* 2010;(8):CD007429. Epub 2010 Aug 04.
55. Phillips AM, Smart C, Groom AF. Acromioclavicular dislocation. Conservative or surgical therapy. *Clin Orthop Relat Res.* 1998 Aug;(353):10-7.
56. Smith TO, Chester R, Pearse EO, Hing CB. Operative versus non-operative management following Rockwood grade III acromioclavicular separation: a meta-analysis of the current evidence base. *J Orthop Traumatol.* 2011 Mar;12(1):19-27. Epub 2011 Feb 23.
57. Malcapi C, Grassi G, Oretti D. Posterior dislocation of the acromio-clavicular joint: a rare or an easily overlooked lesion? *Ital J Orthop Traumatol.* 1978 Apr;4(1):79-83.

- 58.** Millett PJ, Braun S, Gobezie R, Pacheco IH. Acromioclavicular joint reconstruction with coracoacromial ligament transfer using the docking technique. *BMC Musculoskelet Disord.* 2009;10(6):6. Epub 2009 Jan 14.
- 59.** Verhaven E, Casteleyn PP, De Boeck H, Handelberg F, Haentjens P, Opdecam P. Surgical treatment of acute type V acromioclavicular injuries. A prospective study. *Acta Orthop Belg.* 1992;58(2):176-82.
- 60.** Fraser-Moodie JA, Shortt NL, Robinson CM. Injuries to the acromioclavicular joint. *J Bone Joint Surg Br.* 2008 Jun;90(6):697-707.
- 61.** Rios CG, Mazzocca AD. Acromioclavicular joint problems in athletes and new methods of management. *Clin Sports Med.* 2008 Oct;27(4):763-88.
- 62.** Dimakopoulos P, Panagopoulos A, Syggelos SA, Panagiotopoulos E, Lambiris E. Double-loop suture repair for acute acromioclavicular joint disruption. *Am J Sports Med.* 2006 Jul;34(7):1112-9. Epub 2006 Feb 13.
- 63.** Salzmann GM, Walz L, Buchmann S, Glabgyl P, Venjakob A, Imhoff AB. Arthroscopically assisted 2-bundle anatomical reduction of acute acromioclavicular joint separations. *Am J Sports Med.* 2010 Jun;38(6):1179-87. Epub 2010 May 04.
- 64.** Scheibel M, Dröschel S, Gerhardt C, Kraus N. Arthroscopically assisted stabilization of acute high-grade acromioclavicular joint separations. *Am J Sports Med.* 2011 Jul;39(7):1507-16. Epub 2011 Mar 24.
- 65.** Eschler A, Gradl G, Gierer P, Mittlmeier T, Beck M. Hook plate fixation for acromioclavicular joint separations restores coracoclavicular distance more accurately than PDS augmentation, however presents with a high rate of acromial osteolysis. *Arch Orthop Trauma Surg.* 2012 Jan;132(1):33-9. Epub 2011 Oct 02.
- 66.** Chiang CL, Yang SW, Tsai MY, Kuen-Huang Chen C. Acromion osteolysis and fracture after hook plate fixation for acromioclavicular joint dislocation: a case report. *J Shoulder Elbow Surg.* 2010 Jun;19(4):e13-5. Epub 2010 Mar 19.
- 67.** Schindler A, Schmid JP, Heyse C. [Temporary fixation with the Baiser hook plate in the treatment of a fresh and complete acromioclavicular joint dislocation. Results of the follow-up of 41 patients]. *Unfallchirurg.* 1985 Dec;88(12):533-40. German.
- 68.** Leidel BA, Braunstein V, Pilotto S, Mutschler W, Kirchhoff C. Mid-term outcome comparing temporary K-wire fixation versus PDS augmentation of Rockwood grade III acromioclavicular joint separations. *BMC Res Notes.* 2009;2:84. Epub 2009 May 09.
- 69.** Dumrongwanich P, Piyapittayanum P. Outcomes of percutaneous K-wire fixation for AC joint separation type III. *J Med Assoc Thai.* 2009 Dec;92(Suppl 6):S211-6.
- 70.** Busby BR, Bailey LJ, Proffit WR, Phillips C, White RP Jr. Long-term stability of surgical class III treatment: a study of 5-year postsurgical results. *Int J Adult Orthodon Orthognath Surg.* 2002 Fall;17(3):159-70.
- 71.** Tomlinson DP, Altchek DW, Davila J, Cordasco FA. A modified technique of arthroscopically assisted AC joint reconstruction and preliminary results. *Clin Orthop Relat Res.* 2008 Mar;466(3):639-45. Epub 2008 Feb 10.
- 72.** Sage FP, Salvatore JE. Injuries of the acromioclavicular joint: a study of results in 96 patients. *South Med J.* 1963 May;56(May):486-95.
- 73.** Urist MR. Complete Dislocation of the Acromioclavicular Joint. *J Bone Joint Surg Am.* 1963 Dec;45(Dec):1750-3.
- 74.** Weaver JK, Dunn HK. Treatment of acromioclavicular injuries, especially complete acromioclavicular separation. *J Bone Joint Surg Am.* 1972 Sep;54(6):1187-94.
- 75.** Colosimo AJ, Hummer CD 3rd, Heidt RS Jr. Aseptic foreign body reaction to Dacron graft material used for coracoclavicular ligament reconstruction after type III acromioclavicular dislocation. *Am J Sports Med.* 1996 Jul-Aug;24(4):561-3.
- 76.** Dahl E. Follow-up after coracoclavicular ligament prosthesis for acromioclavicular joint dislocation [abstract]. *Acta Chir Scand.* 1981;506:96.
- 77.** Eskola A, Vainionpää S, Korkala O, Rokkanen P. Acute complete acromioclavicular dislocation. A prospective randomized trial of fixation with smooth or threaded Kirschner wires or cortical screw. *Ann Chir Gynaecol.* 1987;76(6):323-6.
- 78.** Mallon WJ, Bronec PR, Spinner RJ, Levin LS. Suprascapular neuropathy after distal clavicle excision. *Clin Orthop Relat Res.* 1996 Aug;(329):207-11.